



Emergence and treatment of chikungunya arthritis

Ravi Sutaria^a, Jose K. Amaral^b, and Robert T. Schoen^a

Purpose of review

To review the emergence, clinical features, pathogenesis, and treatment of acute chikungunya (CHIK) fever and chronic CHIK arthritis.

Recent findings

Since 2004, CHIK, an arboviral infection, has spread throughout the world, infecting millions of people. The illness occurs in two phases: an acute viremic infection followed by chronic arthritis. In less developed countries, there are limited resources and effective treatment. For acutely ill CHIK fever patients, management is symptomatic. The treatment of chronic CHIK arthritis should be determined by an understanding of pathogenesis. Is chronic CHIK arthritis a persistent viral infection or a postinfectious inflammatory process? Multiple proinflammatory cytokines, chemokines, and growth factors have been identified in chronic CHIK arthritis. Attempts to isolate CHIK virus from synovial fluid have been unsuccessful. Given pathogenetic similarities (as well as differences) compared with rheumatoid arthritis and the painful, disabling nature of the arthritis, it is not surprising that disease-modifying antirheumatic drugs such as methotrexate have begun to be used.

Summary

CHIK infection has emerged with major arthritic epidemics for which evidence-based therapy is limited. But there is an opportunity to improve the treatment of chronic CHIK arthritis and, from this disease, to gain understanding of the pathogenesis and treatment of inflammatory arthritis more generally.

Keywords

chikungunya fever, chikungunya virus, chronic postchikungunya arthritis, methotrexate, postviral inflammatory arthritis

INTRODUCTION

Chikungunya (CHIK) fever (CHIKF), caused by the CHIK virus (CHIKV), is a rapidly emerging, global pandemic. CHIKV is a single-stranded RNA virus of the *Togaviridae* family that includes arthritogenic alphaviruses such as the Ross River Virus and neuropathic viruses such as Western equine encephalitis virus [1]. Since 2004, the emergence of CHIKF has resulted from the global spread of two mosquito vectors, *Aedes aegypti* and *Aedes albopictus*, that carry CHIKV, migrating from Africa and Asia to cause disease throughout Africa, Asia, Oceania, Europe, and the Americas – with millions of cases reported [2].

Vector spread throughout tropical and subtropical regions has been possible because of rapidly expanding urban populations, limited vector control, globalization promoting human migration, climate change, and increased environmental disasters (i.e., flooding) [3]. Almost all cases are arthropod-borne, but intrapartum maternal–fetal transmission and transmission via blood products and organ transplantation have occurred [4].

To date, over 45 countries have reported CHIKV outbreaks, including travel associated cases in 46 of the United States and locally acquired cases in Florida [5]. Phylogenetic studies demonstrate three distinct CHIKV Genotypes: East/Central/South Africa that has spread throughout Africa/Asia/Europe, Asian genotype that spread to the Americas in 2013, and the ancestral West African genotype [2]. CHIKF is causing epidemics of acute illness followed by persistent disabling arthritis. This review will examine the clinical manifestations, pathogenesis, and treatment of both early and late stage disease.

^aDepartment of Rheumatology, Yale University School of Medicine, New Haven, Connecticut, USA and ^bFaculty of Medicine Estácio de Juazeiro do Norte, Juazeiro do Norte, Brazil

Correspondence to Robert T. Schoen, MD, MBA, Clinical Professor of Medicine, Department of Rheumatology, Yale University School of Medicine, 60 Temple Street, Suite 6A, New Haven, CT 06510, USA. Tel: +1 203 687 1578; e-mail: Robert.Schoen@yale.edu

Curr Opin Rheumatol 2018, 30:000–000

DOI:10.1097/BOR.0000000000000486

KEY POINTS

- CHIK, like dengue virus or Zika virus infection, is an emerging arboviral infection, transmitted by *Aedes* mosquitoes, causing explosive epidemics.
- CHIK causes a biphasic illness, acute viremic infection followed in many patients by chronic inflammatory arthritis.
- Because CHIK causes chronic, painful inflammatory arthritis in some patients and because chronic CHIK arthritis may be a postinfectious inflammatory arthritis with parallels to rheumatoid arthritis, disease-modifying drugs, such as methotrexate, are being evaluated.

CLINICAL FEATURES

Early disease

Following exposure to CHIKV, up to 95% of infected individuals develop acute symptoms 2–6 days after an infecting mosquito bite [6]. After this incubation, CHIKF begins abruptly with high fever, polyarthralgia, myalgia, rash, often maculopapular, headache, and back pain [7]. CHIKF is often similar to dengue viral infection. Both diseases present with fever and myalgia and are transmitted by the same mosquito vectors. Generally, however, arthralgias are more prominent in CHIKF and hemorrhage, when present, is a feature of dengue viral infection [7]. Other acute symptoms of CHIKF include intense fatigue, anorexia, nausea, vomiting, and diarrhea [6]. Viremia lasts 5–10 days and can be followed by a 6–21-day post-viremic phase with pyrexia, polyarthralgia/arthritis, lymphadenopathy, fatigue, and anorexia [8,9]. Arthralgias are often symmetrical, affecting ankles, wrists, hands, elbows, shoulders, knees, and feet [10–12]. Joint pain is more distal than proximal, although axial skeleton involvement is noted in up to half of cases. Synovitis is seen in ankles, hands, wrists, toes, and less commonly, in larger joints. Atypical joint involvement includes the spine, temporomandibular, or sternoclavicular joints. There may be ligament pain causing pubalgia and talalgia and myalgias in the arms, thighs, and calves without objective evidence of myositis [13,14].

In addition, many CHIKF patients have dermatologic manifestations. The most common rash is generalized, maculopapular and often pruritic, but nodular, vesicular, bullous, and desquamative skin lesions occur along with vasculitic and aphthous lesions [7,15–17]. Additional skin manifestations include hypermelanosis, hyperpigmentation, photosensitivity, exfoliative dermatitis, and erythema nodosum like lesions. Patients with preexisting skin

disease such as psoriasis may have exacerbations. CHIKF skin lesions affect the extremities, trunk, and face, and tend to be transient, resolving after 2–5 days [14,18].

More severely affected acute CHIKF patients have other extra-articular manifestations. Neurologic complications include encephalitis, facial paralysis, sensorineural deafness, and Guillen–Barre syndrome [19]. Ocular manifestations, including optic neuritis, uveitis, retinitis, and conjunctivitis, are also described [20]. A small number of patients have myocarditis, cardiac arrhythmias, sepsis, and septic shock [21]. During widespread CHIKF epidemics, excess mortality has been reported, primarily in newborns and the elderly [22].

Both nonspecific and specific laboratory abnormalities occur with CHIKF. During acute illness, transient leukopenia and lymphopenia, mild thrombocytopenia, elevated inflammatory markers, and abnormal liver function tests are observed [7]. More specific diagnostic tests are also available. During the viremic phase, CHIKV is detectable by viral culture and reverse transcriptase PCR [1,23]. After about 5 days of illness, following viremia, CHIKF can be diagnosed serologically, by ELISA, or by immunofluorescence [6,24].

Late disease

To describe painful arthritis, the word ‘Chikungunya’ means ‘that which bends up’ in the Tanzanian dialect [25]. The transition from acute CHIKF to chronic CHIK arthritis is variable. Some patients have continuous symptoms, whereas others experience a biphasic illness, acute disease followed by transient remission, and then persistent arthritis [26]. Chronic CHIKV symptoms include arthralgia, arthritis, and edema involving hands, wrists, ankles, and knees, typically in a symmetrical pattern [27,28]. In a Colombian study of 152 patients evaluated 26 weeks after onset of CHIKF, morning stiffness (53.7%), joint edema (49.5%), and polyarthralgia and morning stiffness concurrently (38.2%) were the main arthritic symptoms. Overall, 53.7% of the patients had persistent rheumatologic symptoms at 6 months [26]. Among 88 patients in the US Virgin Islands, chronic arthritis was reported in 93, 57, 47% at 3, 15, 24 months, respectively [29]. Other studies report a 4–82% incidence of persistent, unremitting joint symptoms, ranging from months to years [10,30,31].

To better define the risk of chronic arthritis, a systematic review evaluated 5700 CHIKF patients and found that 25–35% progressed to chronic joint symptoms, with 50% developing inflammatory arthritis characterized as rheumatoid arthritis

(RA), postviral polyarthritis, or seronegative spondylitis [32]. To characterize clinical patterns of arthritis, Javelle *et al.* [33] evaluated 159 individuals and found that 112 with CHIKV arthritis for at least 2 years had chronic inflammatory rheumatism; 33 patients fulfilled criteria for spondyloarthritis, 40 for RA, and 21 for undifferentiated polyarthritis.

In addition to arthritis, a variety of extra-articular manifestations occur with chronic CHIK. In one cohort, new-onset Raynaud's phenomenon developed in the second or third month in 20% of patients [31]. In another report, neurological symptoms including neuropathic pain syndromes, cerebral disorders, sensorineural impairment, and paresthesia's were reported, as well as depression [10]. Also present were carpal/tarsal/cubital tunnel syndromes, bursitis, tenosynovitis, and frank synovitis. Some patients had digestive disorders. Considering the large numbers of individuals affected, these widespread and severe symptoms underscore the severity of pain and disability presented by chronic CHIKV infection [14].

PATHOGENESIS

Early disease

During acute CHIKF, a high viral load develops quickly with viral replication in musculoskeletal tissues, particularly tissue fibroblasts, epithelial cells, endothelial cells and macrophages [34]. Viremia promotes a robust immune response dominated by plasmacytoid dendritic cells, monocytes and lymphocytes and a rapid rise in plasma levels of IFN- α and IFN- γ . Control of viremia is IFN- α dependent and rising IFN- α levels coincide with onset of symptoms [10,35]. Several animal studies demonstrate that CHIK infection is lethal in type 1 interferon deficient mice and that mice lacking IFN- α/β have severe arthritic symptoms [36,37]. Similarly, a strong interferon response correlates with milder disease in alphavirus infected mice [38]. In acutely infected patients, elevated viral load and defective interferon type 1 signaling also correlate with disease severity and symptoms [36]. To promote viral replication and signaling, alphaviruses have developed mechanisms to inhibit host interferon induction [39].

A complex array of other proinflammatory/anti-inflammatory cytokines, chemokines, and growth factors are involved in monocyte trafficking and activation of natural killer (NK)/T cells in early CHIKF [40]. Elevated levels of IL-1Ra, IL-6, IL-8, IL-10, IL-13, IL-16, IP-10, MCP-1, MIP1Beta, CCL2, migration inhibition factor, CCL4, granulocyte colony stimulating factor, granulocyte-macrophage

colony stimulating factor (GM-CSF), and vascular endothelial growth factor have all been reported [24,41,42,43[■]].

Transition from early to late disease

As patients with CHIKF transition from acute to chronic disease, typically between 4 weeks and 3 months after infection, proinflammatory cytokines such as IL-6 and IL-17 persist, as do increased serum concentrations of the growth factor GM-CSF [35]. The mechanism of progression from acute infection to persistent arthritis is uncertain, but could include macrophage virus tropism, local viral persistence, or unabated inflammatory responses [14]. However, attempts to recover CHIKV from synovial fluid have been unsuccessful, suggesting that the pathogenesis of chronic CHIK arthritis may be a postinfectious, inflammatory process [44[■]]. CHIKV RNA has also not been found in synovium during chronic disease [44[■],45,46].

Molecular mimicry is a possible mechanism for chronic CHIK arthritis, but no specific autoantigen has been described [47[■]]. In both mice and human models, CD4+ T cells and improperly functioning NK cells have been linked to chronic arthritis [40,48]. It is postulated that myeloid cells, including cellular debris-clearing macrophages, may act as a source of pathogen-associated molecular patterns that generate chronic inflammation [43[■]]. These several lines of evidence suggest that progression from acute infection to chronic CHIKV arthritis could result from a postinfectious, inflammatory host response that resembles other auto-immune, inflammatory rheumatic diseases.

Late disease

In addition to the failure to demonstrate CHIKV in synovial fluid in chronic CHIK arthritis patients, the cytokine profile in chronic infection mimics the cytokines seen in RA, including IFN- α , IL-1 β , IL-5, IL-6, IL-10, IL-7, IL-15, and TNF- α [49]. Despite these similarities, 95.8% of CHIKV arthritis patients are rheumatoid factor and anticitrulline antibody negative [50].

IL-17 may drive chronic CHIK inflammation, inciting extracellular matrix/bone destruction through stimulation of IL-6, tumor necrosis factor, IL-1, matrix metalloproteinases proteinases, and the receptor activator of nuclear factor kB-receptor activator of nuclear factor kB ligand (RANKL) system [51]. As in RA, IL-6 participates in chronic CHIKV arthritis, in part by stimulating RANKL and inhibiting osteoprotegerin released by osteoblasts. In mouse models of chronic CHIK arthritis,

osteoclastogenesis and substantial bone loss occur via this pathway [52–55]. Elevated levels of IL-1 β and IL-6 along with decreased regulated on activation, normal T cell expressed and secreted correlate with more severe disease, whereas increased IL-1 and IL-8 coincide with more destructive arthritis demonstrating the complex, concerted interaction of multiple proinflammatory factors [46,50].

TREATMENT

None of the treatments to be discussed have been approved by the Food and Drug Administration or other regulatory authority.

Prevention

Vector control strategies of *Aedes* mosquitoes have been used, particularly in affluent countries with temperate climates, but have had limited success in India, Africa, and other major reservoirs of disease [56]. Alphavirus vaccines, including an effective CHIKV vaccine, are technically achievable, but have not yet found a viable commercial market. This limitation is changing as a result of the spread of the CHIK pandemic, tourism, and the needs of the military [57]. Vaccines have reached human trials and may have a preventive impact in the future [58].

Early disease

A variety of antiviral strategies are under investigation in the treatment of CHIKF and other alphavirus infections, but none, including chloroquine, acyclovir, ribavirin, IFN- α , corticosteroids, and newer agents, including favipiravir, the trypanosomiasis drug suramin, and the turmeric-derived compound curcumin have been validated [59,60–64]. At the present time, early treatment is supportive care, including rest, adequate hydration, antipyretics, and analgesics [65]. Severely ill and frail patients may need to be hospitalized for intravenous fluids and monitoring of electrolyte imbalances, organ dysfunction, pain, and fever. As corticosteroids are immunosuppressive, NSAIDs have been recommended for early treatment of joint symptoms [1,9], but concern exists that aspirin or NSAIDs be used cautiously if there is possible dengue coinfection with potential for hemorrhagic complications [6]. Thus, in acute infection, acetaminophen, tramadol, codeine, or oxycodone are preferred [66]. Maintaining mobility is important.

Following acute infection, some patients experience postacute (week 4 to month 3) symptoms of tendinitis, arthritis, and arthralgias. Treatment includes NSAIDs, corticosteroids for severe arthritic

manifestations, and gabapentin and pregabalin for neuropathic pain control [9]. Acute symptoms often resolve within weeks, but some patients remain symptomatic with joint pain and depression [33].

Late disease

Chronic CHIKV arthritis causes joint damage and impacts quality of life as severely as RA [46]. The goals of treatment of chronic CHIK arthritis include pain relief and preventing joint destruction. This phase of the illness is increasingly referred to as post-CHIK chronic inflammatory rheumatism (pCHIK-CIR) [29,33]. Treatment options for pCHIK-CIR include NSAIDs, corticosteroids, hydroxychloroquine (HCQ), sulfasalazine (SSZ), leflunomide, methotrexate (MTX), and biologics [33] (Table 1).

NSAIDs and corticosteroids

Corticosteroids improved tenosynovitis, polyarthritis, and ability to ambulate in patients treated months after acute illness [31]. In 147 patients with pCHIK-CIR, there was better symptomatic improvement with corticosteroids compared with NSAIDs and acetaminophen [67]. Padmakumar *et al.* [68] demonstrated that an NSAID (aceclofenac 200 mg/day) in combination with corticosteroids (prednisolone 10 mg/day) improved quality of life and reduced pain more than NSAID monotherapy or combination NSAID/HCQ (400 mg/day) therapy. No benefit was achieved with the addition of HCQ.

Hydroxychloroquine and chloroquine

Antimalarial therapy has not been demonstrated to be effective in pCHIK-CIR. Sebastian *et al.* [69] found no reduction in joint pain comparing chloroquine with placebo. Other studies demonstrated no difference in the duration of arthralgia or viremia with chloroquine vs. placebo [70]. Chloroquine was not superior to meloxicam in controlling chronic arthritis pain in 70 pCHIK-CIR patients [8,71].

Methotrexate

If chronic CHIKV arthritis may be a postinfectious, inflammatory arthritis, MTX therapy should be considered [72]. MTX increases adenosine and inhibits proinflammatory cytokines such as IL-1, IL-6, IL-8, and TNF- α [73]. These cytokines, especially IL-1, IL-6, IL-17, have been associated with greater disease severity in both RA and chronic CHIKV arthritis [49,51]. There is no prospective, placebo controlled trial evaluating the efficacy and safety of MTX monotherapy in the treatment of chronic CHIK arthritis [74]. We believe that such a study is warranted and have had success treating individual chronic CHIK arthritis patients with MTX (Fig. 1).

Table 1. Rheumatic disease treatment in chronic chikungunya arthritis

Drug	Type of study	Number of patients	Outcome measure	Evidence of efficacy	Reference, country
NSAIDs/ Corticosteroids/ Hydroxychloroquine	Prospective Randomized Parallel Group Study	120	VAS ADL IADL	Group C [aceclofenac (200 mg/day) + prednisone (10 mg/day)] & Group D [aceclofenac (200 mg/day) + prednisone (10 mg/day) + HCG (400 mg/day)] showed statistically significant improvements in VAS/ADL/IADL compared to Group A (aceclofenac alone) & Group B (aceclofenac + HCG)	Padmakumar <i>et al.</i> [68], India
Hydroxychloroquine	Double-blinded, placebo controlled, randomized trial	54	Viremia; Duration of febrile arthralgia	HCG group (600 mg Day 1 → 300-mg BID Days 2/3 → 300-mg QD) showed no significant difference between placebo group in terms of duration of febrile arthralgia or decrease of viremia between days 1 and 3. At Day 200, patients who received chloroquine treatment complained of arthralgia more frequently than those who received placebo (P 0.01)	De Lamballerie <i>et al.</i> [70], French Reunion Island
Chloroquine/Meloxicam	24-week, 2-arm, parallel efficacy trial	70	VAS; Cytokine levels	Although both groups showed clinical improvements, no significant difference found between the chloroquine (250 mg/day) and meloxicam (7.5 mg/day) in terms of VAS and inflammatory cytokine levels. No advantage of chloroquine over meloxicam to treat early musculoskeletal pain and arthritis following acute CHIK virus infection. Therapeutic efficacy of chloroquine was not ruled out	Chopra <i>et al.</i> [71], India
Methotrexate/ sulfasalazine/ Hydroxychloroquine	24-week prospective, randomized parallel group open-label study	72	DAS28-ESR; EULAR good response; HAQ; pain VAS	Patients with persistent CHIKF arthritis received either triple combination therapy (MTX 15 mg/week, SSZ 1 g/day, HCG 400 mg/day) vs. monotherapy with HCG 400 mg/day. At 24 weeks, combination therapy group showed significant improvement in both DAS28-ESR and HAQ. At study end pain VAS was significantly less in combination therapy group	Ravindran and Alias [75], India
Methotrexate/ sulfasalazine/ Hydroxychloroquine	Prospective	16	TJC; SJC; ESR; DAS28; HAQ	All patients given NSAIDs (Etoricoxib 90 mg/day) for 2 weeks and 2–4 weeks of steroid (prednisolone 5–10 mg/day). Patients then given sulfasalazine 1–2 g/day with HCG 200 mg/day and subsequently methotrexate added to those having poor to moderate response after 3 months. Treatment with sulfasalazine with and without methotrexate produced good response in 71.4 and 12.5%, respectively	Ganu and Ganu [76], India
Methotrexate	Retrospective	159	MTX treatment considered successful if there was no need for dose escalation or additional drug therapy	MTX 15 mg/week was clinically effective in 54 of the 72 patients (75%) with efficacy of 67% in rheumatoid arthritis patients, 80% in spondyloarthritis, 100% in undifferentiated polyarthritis	Javelle <i>et al.</i> [33], French Reunion Island

ADL, activities of daily living; BID, twice daily; CHIK, chikungunya; CHIKF, chikungunya fever; DAS28-ESR, disease activity score 28-joint count erythrocyte sedimentation rate; EULAR-European League Against Rheumatism; HAQ, Health Assessment Questionnaire; HCG, hydroxychloroquine; IADL, instrumental activities of daily living; MTX, methotrexate; QD, once daily; SJC, Swollen joint count; SSZ, sulfasalazine; TJC, tender joint count; VAS, visual analogue scale.

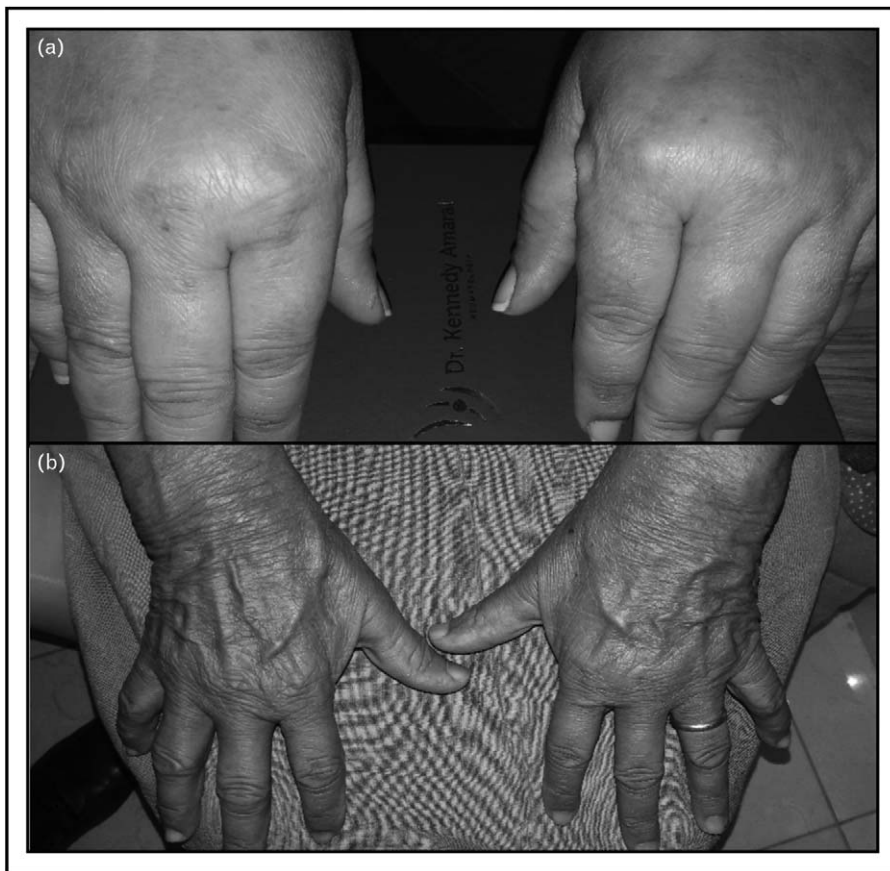

FIGURE 1. A patient with chronic chikungunya arthritis. (a) Before methotrexate treatment. (b) Following methotrexate 7.5 mg/week for 4 weeks.

In the best available CHIK arthritis MTX study, Ravindran and Alias [75^{***}] demonstrated superiority of triple therapy (MTX 15 mg/week, HCQ 400 mg/day, and SSZ 1 g/day) compared with HCQ

monotherapy (DAS28-ESR < 3.2 at 24 weeks, 84 vs. 14%, respectively, P value < 0.0001) (Fig. 2).

Other uncontrolled studies support the use of MTX in chronic CHIK arthritis. Ganu and Ganu [76] found that adding MTX to SSZ and HCQ in non-responders after 3 months resulted in significantly better clinical responses. Javelle *et al.* [33] noted ‘good therapeutic response’ in 75% of the 72 patients treated with MTX 15 mg/weekly with pCHIK-CIR who met criteria for RA, spondyloarthritis, or undifferentiated polyarthritis.

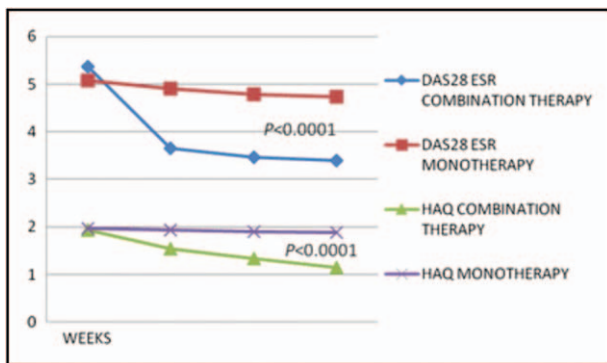


FIGURE 2. Triple therapy including methotrexate is superior to hydroxychloroquine. Disease activity and disability at weeks 8th, 16th, and 24th. DAS, disease activity score; HAQ, Health Assessment Questionnaire in Combination therapy with methotrexate, sulfasalazine, hydroxychloroquine vs. monotherapy with hydroxychloroquine. Reproduced from [75^{***}].

Biologic therapy

There is limited information regarding use of biologic therapies in pCHIK-CIR. In a murine model, anti-TNF- α therapy with etanercept exacerbated tissue damage in mice with alphaviral arthritis [77]. During the CHIK outbreak on Reunion Island, however, 12 patients with chronic CHIK arthritis who escalated to treatment with antitumor necrosis factor therapy after MTX failure showed ‘beneficial effect’ [33]. Significantly, another report from the Dominican Republic indicated that 53 of 328 RA patients developed CHIKV arthritis while on prior

biologic therapy, suggesting that biologic therapy does not protect against CHIK arthritis [78]. In a murine model, the CD4+ T-cell suppressive drug fingolimod was joint protective [79]. Also in a mouse model, Miner *et al.* [80] showed benefit for the CTLA-4 fusion protein, abatacept, used in the treatment of RA, when combined with anti-CHIKV neutralizing antibodies.

CONCLUSION

In just 10 years, CHIKF has become a global disease affecting millions of people. Attempts to limit the *Aedes* mosquito vectors or to prevent the disease through vaccination may have a future impact on this disease. In the meantime, primary care physicians, practicing in CHIK endemic areas, treat acute disease symptomatically as we have outlined in this review.

For the rheumatologist, treating patients with chronic CHIK arthritis, a central question about pathogenesis will determine how the disease should be managed. CHIKF begins as an alphavirus infection. Evidence, by no means certain, suggests that in the progression of acute illness to chronic arthritis, the infection may become a postinfectious inflammatory arthritis. This may provide treatment options beyond supportive management with disease-modifying drugs such as MTX. But before confident recommendations can be made, there is a need for more research both on the pathogenesis of CHIK arthritis and on randomized controlled trials evaluating therapy.

Acknowledgements

None.

Financial support and sponsorship

None.

Conflicts of interest

There are no conflicts of interest.

REFERENCES AND RECOMMENDED READING

Papers of particular interest, published within the annual period of review, have been highlighted as:

- of special interest
- of outstanding interest

1. Suhrbier A, Jaffar-Bandjee MC, Gasque P. Arthritogenic alphaviruses – an overview. *Nat Rev Rheumatol* 2012; 8:420–429.
2. Zeller H, Van Bortel W, Sudre B. Chikungunya: its history in Africa and Asia and its spread to new regions in 2013–2014. 2016; 214:S436–S440.
3. Peterson AT. Shifting suitability for malaria vectors across Africa with warming climates. *BMC Infect Dis* 2009; 9:59.
4. Panning M, Grywna K, van Esbroeck M, *et al.* Chikungunya fever in travelers returning to Europe from the Indian Ocean region, 2006. *Emerg Infect Dis* 2008; 14:416–422.
5. Laboratory-confirmed chikungunya virus disease cases reported to ArboNET by state or territory — United States, 2016, CDC. Available at: <https://www.cdc.gov/chikungunya/pdfs/2016/2016Table.pdf>. [Accessed November 1, 2017]
6. Simon F, Javelle E, Oliver M, *et al.* Chikungunya virus infection. *Curr Infect Dis Rep* 2011; 13:218–228.
7. Staples JE, Breiman RF, Powers AM. Chikungunya fever: an epidemiological review of a re-emerging infectious disease. *Clin Infect Dis* 2009; 49: 942–948.
8. Goupil BA, Mores CN. A review of chikungunya virus-induced arthralgia: clinical manifestations, therapeutics, and pathogenesis. *Open Rheumatol J* 2016; 10:129–140.
9. Simon F, Javelle E, Cabie A, *et al.* French guidelines for the management of chikungunya (acute and persistent presentations). November 2014. *Med Mal Infect* 2015; 45:243–263.
10. Borgherini G, Poubeau P, Staikowsky F, *et al.* Outbreak of chikungunya on Reunion Island: early clinical and laboratory features in 157 adult patients. *Clin Infect Dis* 2007; 44:1401–1407.
11. Sourisseau M, Schilte C, Casartelli N, *et al.* Characterization of reemerging chikungunya virus. *PLoS Pathog* 2007; 3:e89.
12. Yergolkar PN, Tandale BV, Arankalle VA, *et al.* Chikungunya outbreaks caused by African genotype, India. *Emerg Infect Dis* 2006; 12:1580–1583.
13. Staikowsky F, Talarmin F, Grivard P, *et al.* Prospective study of Chikungunya virus acute infection in the Island of La Reunion during the 2005–2006 outbreak. *PLoS One* 2009; 4:e7603.
14. Thiberville SD, Moya N, Dupuis-Maguiraga L, *et al.* Chikungunya fever: epidemiology, clinical syndrome, pathogenesis and therapy. *Antiviral Res* 2013; 99:345–370.
15. Arroyo-Avila M, Vila LM. Rheumatic manifestations in patients with chikungunya infection. *P R Health Sci J* 2015; 34:71–77.
16. Economopoulou A, Dominguez M, Helyncx B, *et al.* Atypical chikungunya virus infections: clinical manifestations, mortality and risk factors for severe disease during the 2005–2006 outbreak on Reunion. *Epidemiol Infect* 2009; 137:534–541.
17. Pialoux G, Gauzere BA, Jaureguiberry S, Strobel M. Chikungunya, an epidemic arbovirolosis. *Lancet Infect Dis* 2007; 7:319–327.
18. Robin S, Ramful D, Zettor J, *et al.* Severe bullous skin lesions associated with chikungunya virus infection in small infants. *Eur J Pediatr* 2010; 169:67–72.
19. Cerny T, Schwarz M, Schwarz U, *et al.* The range of neurological complications in Chikungunya fever. *Neurocrit Care* 2017; 27:447–457.
20. Mahendradas P, Avadhani K, Shetty R. Chikungunya and the eye: a review. *J Ophthalmic Inflamm Infect* 2013; 3:35.
21. Ferreira-Sarmiento S, Lastra-Terán KP, de la Rosa D, Viasus D. Infección grave por el virus del chikungunya (Severe chikungunya virus infection). *Revista Salud Uninorte* 2015; 31:631–641.
22. Mavalankar D, Shastri P, Bandyopadhyay T, *et al.* Increased mortality rate associated with chikungunya epidemic, Ahmedabad, India. *Emerg Infect Dis* 2008; 14:412–415.
23. Weaver SC, Lecuit M. Chikungunya virus and the global spread of a mosquito-borne disease. *N Engl J Med* 2015; 372:1231–1239.
24. Wilson JA, Prow NA, Schroder WA, *et al.* RNA-Seq analysis of chikungunya virus infection and identification of granzyme A as a major promoter of arthritic inflammation. *PLoS Pathog* 2017; 13:e1006155.
25. Robinson MC. An epidemic of virus disease in Southern Province, Tanganyika territory, in 1952–1953. *Trans R Soc Trop Med Hyg* 1955; 49:28–32.
26. Rodríguez-Morales AJ, Gil-Restrepo AF, Ramírez-Jaramillo V, *et al.* Postchikungunya chronic inflammatory rheumatism: results from a retrospective follow-up study of 283 adult and child cases in La Virginia, Risaralda, Colombia. *F1000Res* 2016; 5:360.
27. Krutikov M, Manson J. Chikungunya virus infection: an update on joint manifestations and management. *Rambam Maimonides Med J* 2016; 1–7.
28. Schilte C, Staikowsky F, Couderc T, *et al.* Chikungunya virus-associated long-term arthralgia: a 36-month prospective longitudinal study. *PLoS Negl Trop Dis* 2013; 7:e2137.
29. Feldstein LR, Rowhani-Rahbar A, Staples JE, *et al.* Persistent arthralgia associated with chikungunya virus outbreak, US Virgin Islands, December 2014–February 2016. *Emerg Infect Dis* 2017; 23:673–676.
30. Robin S, Ramful D, Le Seach F, *et al.* Neurologic manifestations of pediatric chikungunya infection. *J Child Neurol* 2008; 23:1028–1035.
31. Simon F, Parola P, Grandadam M, *et al.* Chikungunya infection: an emerging rheumatism among travelers returned from Indian Ocean islands. Report of 47 cases. *Medicine (Baltimore)* 2007; 86:123–137.
32. Rodríguez-Morales AJ, Cardona-Ospina JA, Fernanda Urbano-Garzón S, Sebastian Hurtado-Zapata J. Prevalence of post-chikungunya infection chronic inflammatory arthritis: a systematic review and meta-analysis. *Arthritis Care Res* 2016; 68:1849–1858.
33. Javelle E, Ribera A, Degasne I, *et al.* Specific management of postchikungunya rheumatic disorders: a retrospective study of 159 cases in Reunion Island from 2006–2012. *PLoS Negl Trop Dis* 2015; 9:e0003603.
34. Broeckel R, Fox JM, Haese N, *et al.* Therapeutic administration of a recombinant human monoclonal antibody reduces the severity of chikungunya virus disease in rhesus macaques. *PLoS Negl Trop Dis* 2017; 11:e0005637.

35. Wauquier N, Becquart P, Nkoghe D, *et al.* The acute phase of Chikungunya virus infection in humans is associated with strong innate immunity and T CD8 cell activation. *J Infect Dis* 2011; 204:115–123.
36. Couderc T, Chretien F, Schilte C, *et al.* A mouse model for Chikungunya: young age and inefficient type-I interferon signaling are risk factors for severe disease. *PLoS Pathog* 2008; 4:e29.
37. Gardner CL, Burke CW, Higgs ST, *et al.* Interferon-alpha/beta deficiency greatly exacerbates arthritogenic disease in mice infected with wild-type chikungunya virus but not with the cell culture-adapted live-attenuated 181/25 vaccine candidate. *Virology* 2012; 425:103–112.
38. Poddar S, Hyde JL, Gorman MJ, *et al.* The interferon-stimulated gene IFITM3 restricts infection and pathogenesis of arthritogenic and encephalitic alphaviruses. *J Virol* 2016; 90:8780–8794.
39. Fros JJ, Pijlman GP. Alphavirus infection: host cell shut-off and inhibition of antiviral responses. *Viruses* 2016; 8:166. doi: 10.3390/v8060166.
40. Thanapati S, Ganu M, Giri P, *et al.* Impaired NK cell functionality and increased TNF-alpha production as biomarkers of chronic chikungunya arthritis and rheumatoid arthritis. *Hum Immunol* 2017; 78:370–374.
41. Chow A, Her Z, Ong EK, *et al.* Persistent arthralgia induced by chikungunya virus infection is associated with interleukin-6 and granulocyte macrophage colony-stimulating factor. *J Infect Dis* 2011; 203:149–157.
42. Dupuis-Maguiraga L, Noret M, Brun S, *et al.* Chikungunya disease: infection-associated markers from the acute to the chronic phase of arbovirus-induced arthralgia. *PLoS Negl Trop Dis* 2012; 6:e1446.
43. Her Z, Malleret B, Chan M, *et al.* Active infection of human blood monocytes by chikungunya virus triggers an innate immune response. *J Immunol* 2010; 184:5903–5913.
- Chikungunya virus (CHIKV) can be detected in monocytes in acutely infected patients. Persistent monocyte infection in synovial tissue could contribute to the pathology of chronic chikungunya (CHIK) arthritis.
44. Chang AY, Martins KAO, Encinales L, *et al.* A cross-sectional analysis of chikungunya arthritis patients 22-months post-infection demonstrate no detectable viral persistence in synovial fluid. *Arthritis Rheumatol* 2017; doi: 10.1002/art.40383. [Epub ahead of print]
- In a chronic CHIK arthritis cohort, analysis of synovial fluid by reverse-transcriptase PCR, culture, and mass spectrometry failed to detect CHIKV.
45. Hoarau JJ, Jaffar Bandjee MC, Krejbich Trotot P, *et al.* Persistent chronic inflammation and infection by chikungunya arthritogenic alphavirus in spite of a robust host immune response. *J Immunol* 2010; 184:5914–5927.
46. Malvy D, Ezzedine K, Mamani-Matsuda M, *et al.* Destructive arthritis in a patient with chikungunya virus infection with persistent specific IgM antibodies. *BMC Infect Dis* 2009; 9:200.
47. Reddy V, Desai A, Krishna SS, Vasanthapuram R. Molecular mimicry between chikungunya virus and host components: a possible mechanism for the arthritic manifestations. *PLoS Negl Trop Dis* 2017; 11:e0005238.
- Molecular mimicry of the E1 protein by host proteins could contribute to the pathology of CHIK arthritis.
48. Gasque P, Jaffar-Bandjee MC. Blunting CHIKV infection by keeping T cells in check. *Sci Transl Med* 2017; 9. doi: 10.1126/scitranslmed.aam6567.
49. Ng LF, Chow A, Sun YJ, *et al.* IL-1beta, IL-6, and RANTES as biomarkers of chikungunya severity. *PLoS One* 2009; 4:e4261.
50. Jaller Raad J, Segura Rosero A, Vidal Martinez J, *et al.* Immunological response of a population from the Caribbean region of Colombia infected with the chikungunya virus. *Rev Colomb Reumatol* 2016; 23:85–91.
51. Miossec P, Korn T, Kuchroo VK. Interleukin-17 and type 17 helper T cells. *N Engl J Med* 2009; 361:888–898.
52. Chen W, Foo SS, Rulli NE, *et al.* Arthritogenic alphaviral infection perturbs osteoblast function and triggers pathologic bone loss. *Proc Natl Acad Sci U S A* 2014; 111:6040–6045.
53. Noret M. Interleukin 6, RANKL, and osteoprotegerin expression by chikungunya virus-infected human osteoblasts. *J Infect Dis* 2012; 206:455–457.
54. Rodriguez-Morales AJ, Hoyos-Guapacha KL, Vargas-Zapata SL, *et al.* Would be IL-6 a missing link between chronic inflammatory rheumatism and depression after chikungunya infection? *Rheumatol Int* 2017; 37:1149–1151.
55. Sepulveda-Delgado J, Vera-Lastra OL, Trujillo-Murillo K, *et al.* Inflammatory biomarkers, disease activity index, and self-reported disability may be predictors of chronic arthritis after chikungunya infection: brief report. *Clin Rheumatol* 2017; 36:695–699.
56. Reiter P, Fontenille D, Paupy C. *Aedes albopictus* as an epidemic vector of chikungunya virus: another emerging problem? *Lancet Infect Dis* 2006; 6:463–464.
57. Weaver SC, Osorio JE, Livengood JA, *et al.* Chikungunya virus and prospects for a vaccine. *Expert Rev Vaccines* 2012; 11:1087–1101.
58. Goo L, Dowd KA, Lin TY, *et al.* A virus-like particle vaccine elicits broad neutralizing antibody responses in humans to all chikungunya virus genotypes. *J Infect Dis* 2016; 214:1487–1491.
59. Abdelnabi R, Neyts J, Delang L. Antiviral strategies against chikungunya virus. *Methods Mol Biol* 2016; 1426:243–253.
- There are currently no effective antiviral drugs for chikungunya fever.
60. Albulescu IC, van Hoolwerff M, Wolters LA, *et al.* Suramin inhibits chikungunya virus replication through multiple mechanisms. *Antiviral Res* 2015; 121:39–46.
61. Delang L, Segura Guerrero N, Tas A, *et al.* Mutations in the chikungunya virus nonstructural proteins cause resistance to favipiravir (T-705), a broad-spectrum antiviral. *J Antimicrob Chemother* 2014; 69:2770–2784.
62. Gallegos KM, Drusano GL, Brown AN. Chikungunya virus: in vitro response to combination therapy with ribavirin and interferon Alfa 2a. *J Infect Dis* 2016; 214:1192–1197.
63. Her Z, Kam YW, Lin RT, Ng LF. Chikungunya: a bending reality. *Microbes Infect* 2009; 11:1165–1176.
64. Mounce BC, Cesaro T, Carrau L, *et al.* Curcumin inhibits Zika and chikungunya virus infection by inhibiting cell binding. *Antiviral Res* 2017; 142: 148–157.
65. Parashar D, Cherian S. Antiviral perspectives for chikungunya virus. *Biomed Res Int* 2014; 2014:631642.
66. Brito CA, Sohsten AK, Leitao CC, *et al.* Pharmacologic management of pain in patients with chikungunya: a guideline. *Rev Soc Bras Med Trop* 2016; 49:668–679.
67. Sissoko D, Malvy D, Ezzedine K, *et al.* Postepidemic Chikungunya disease on Reunion Island: course of rheumatic manifestations and associated factors over a 15-month period. *PLoS Negl Trop Dis* 2009; 3:e389.
68. Padmakumar B, Jayan JB, Menon RMR, *et al.* Comparative evaluation of four therapeutic regimes in chikungunya arthritis: a prospective randomized parallel-group study. *Indian J Rheumatol* 2009; 4:94–101.
69. Sebastian MR, Lodha R, Kabra SK. Chikungunya infection in children. *Indian J Pediatr* 2009; 76:185–189.
70. De Lamballerie X, Boisson V, Reynier JC, *et al.* On chikungunya acute infection and chloroquine treatment. *Vector Borne Zoonotic Dis* 2008; 8:837–839.
71. Chopra A, Saluja M, Venugopalan A. Effectiveness of chloroquine and inflammatory cytokine response in patients with early persistent musculoskeletal pain and arthritis following chikungunya virus infection. *Arthritis Rheumatol* 2014; 66:319–326.
72. Kennedy Amaral Pereira J, Schoen RT. Management of chikungunya arthritis. *Clin Rheumatol* 2017; 36:2179–2186.
73. Swierkot J, Szechinski J. Methotrexate in rheumatoid arthritis. *Pharmacol Rep* 2006; 58:473–492.
74. Kennedy Amaral J, Sutaria RB, Schoen RT. Treatment of chronic chikungunya arthritis with methotrexate: a systemic review. *Arth Care Res* 2018. doi: 10.1002/acr.23519.
75. Ravindran V, Alias G. Efficacy of combination DMARD therapy vs. hydroxychloroquine monotherapy in chronic persistent chikungunya arthritis: a 24-week randomized controlled open label study. *Clin Rheumatol* 2017; 36:1335–1340.
- In a blinded, prospective study, triple therapy [methotrexate, hydroxychloroquine (HCQ), SSZ] was superior, as measured by DAS28ESR, to HCQ.
76. Ganu MA, Ganu AS. Postchikungunya chronic arthritis – our experience with DMARDs over two year follow up. *J Assoc Physicians India* 2011; 59:83–86.
77. Zaid A, Rulli NE, Rolph MS, *et al.* Disease exacerbation by etanercept in a mouse model of alphaviral arthritis and myositis. *Arthritis Rheum* 2011; 63:488–491.
78. Rosario V, Munoz-Louis R, Valdez T, *et al.* Chikungunya infection in the general population and in patients with rheumatoid arthritis on biological therapy. *Clin Rheumatol* 2015; 34:1285–1287.
79. Teo TH, Chan YH, Lee WW, *et al.* Fingolimod treatment abrogates chikungunya virus-induced arthralgia. *Sci Transl Med* 2017; 9. doi: 10.1126/scitranslmed.aal1333.
80. Miner JJ, Cook LE, Hong JP, *et al.* Therapy with CTLA4-Ig and an antiviral monoclonal antibody controls chikungunya virus arthritis. *Sci Transl Med* 2017; 9. doi: 10.1126/scitranslmed.aah3438.